

The Incidence of Spontaneous Neoplasia in Two Populations of Captive Rhesus Macaques (*Macaca mulatta*)

Heather A. Simmons¹ and Julie A. Mattison²

Abstract

Rhesus macaques (*Macaca mulatta*) are genetically similar to humans and share many characteristics of aging and age-related diseases. They age at approximately three times the rate of humans and develop spontaneous cancers. In both humans and rhesus macaques, cancer incidence increases with age with the greatest incidence in those over 60 years of age and 20 years, respectively. The current survey reports on the incidence of spontaneous neoplasia in two colonies of captive rhesus macaques: the Wisconsin National Primate Research Center colony with 28 years of records and a National Institute on Aging colony with 21 years of records. When categorized by organ and histologic diagnosis, the average age at diagnosis was greater than 20 years for all categories except oral squamous cell carcinoma. Neoplasms of the gastrointestinal system were the most commonly diagnosed, accounting for 48.8% of the cases. Adenocarcinomas of the large intestine were the most prevalent tumor identified. Although there are differences in the biological behavior of cancer in the rhesus macaque when compared with humans, they are a valuable model of comparative oncology. *Antioxid. Redox Signal.* 14, 221–227.

Introduction

AS HUMAN POPULATIONS in many countries age, there is increasing interest in the diseases and conditions associated with aging. Rhesus macaques (*Macaca mulatta*) are an excellent model species for human aging and disease (4, 10, 14). Similarities between rhesus macaques and humans extend to almost all aspects of anatomy, physiology, neurology, endocrinology, immunology, behavior, and aging processes (6). Currently, four of the National Primate Centers, the California National Primate Research Center, the Oregon National Primate Research Center, the Tulane National Primate Research Center, and the Wisconsin National Primate Research Center, maintain colonies of older rhesus macaques specifically set aside for the long-term noninvasive study of aging processes. These aging colonies were established with funding from the National Institute on Aging (NIA) in 1980 and are reserved as a resource for biological, behavioral, social, and clinical studies on the processes, conditions, and characteristics relevant to aging.

Rhesus macaques have a close genetic relationship to humans and have a similar aging phenotype at roughly three times the rate of humans. This species undergoes sexual maturation at 3–5 years of age with median lifespan approximately 25 years and maximum lifespan 40 years of age (4). They are one of the most commonly used long-lived primates in biomedical research.

The positive correlation between increasing age and increasing incidence of neoplasia is well documented in humans. In the United States, cancer is the leading cause of death among women aged 40–69 years old and men 60–79 years (9). There is similar documentation of an increased incidence of neoplasia in rhesus macaques over the age of 20 years (16, 17). These macaques are housed in indoor research facilities where they are fed controlled diets and are not exposed to many of the known and suspected environmental carcinogens, such as ultraviolet radiation, cigarette smoke, or environmental pollution. Thus, rhesus macaques are a good comparative oncology model for the investigation of spontaneous neoplasia and age-related disease.

Previous surveys of spontaneous cancers in *M. mulatta* have revealed that, unlike humans, prostate and lung cancer are rare in aged nonhuman primates (3). Similar to humans, neoplasia affecting the colon is common, although the development of benign and precancerous polyps has not been described in the rhesus macaque (16, 17). Although nonhuman primates are an excellent model species for study of the effectiveness of cancer therapeutics, the management protocols for most aging cohorts do not allow use of chemotherapeutic agents (traditional or novel) or other anticancer therapies. Management protocols do allow surgical intervention for both diagnostic and therapeutic purposes. In this article, we focus on the incidence of all types of spontaneous

¹Wisconsin National Primate Research Center, University of Wisconsin, Madison, Wisconsin.

²Laboratory of Experimental Gerontology, National Institute on Aging, National Institutes of Health, Poolesville, Maryland.

TABLE 1. DISTRIBUTION OF NEOPLASMS IN RHESUS MACAQUES

Neoplasm location	Histologic diagnosis	n	Age (years)	
			Diagnosis ^a	Range
Gastrointestinal		127		
Colon		43		
	Colonic adenocarcinoma	33	24.3	5.6–39.0
	Colonic mucinous adenocarcinoma	9	23.4	13.2–30.4
	Adenoma	1	23.9	
Ileocecolic junction		31		
	Ileocecolic adenocarcinoma	22	25.8	12.3–40.5
	Ileocecolic mucinous adenocarcinoma	9	21.1	17.8–28.6
Cecum		14		
	Cecal adenocarcinoma	8	25.0	19.5–32.5
	Cecal mucinous adenocarcinoma	5	23.6	16.3–29.9
	Leiomyoma	1	28.0	
Cecum and colon		7		
	Cecocolic adenocarcinoma	5	18.2	15.7–20.6
	Cecocolic leiomyosarcoma	1	22.1	
	Cecocolic mucinous adenocarcinoma	1	16.3	
Duodenum		7		
	Carcinoma of the ampulla of Vater	6	26.9	20.0–37.3
	Duodenal adenocarcinoma	1	20.2	
Jejunum/small intestine		7		
	Jejunal adenocarcinoma	7	24.6	17.7–32.0
Oral cavity		6		
	Oral squamous cell carcinoma	6	17.6	10.3–29.3
Liver		5		
	Cystadenoma	2	23.3	19.9–26.8
	Hepatocellular carcinoma	1	14.0	
	Hepatic anaplastic carcinoma	1	20.5	
	Hemangioma	1	15.8	
Parotid gland		3		
	Adenoma	2	23.2	19.5–26.9
	Parotid gland adenocarcinoma	1	27.4	
Ileum		2		
	Ileal adenocarcinoma	1	25.2	
	Ileal mucinous adenocarcinoma	1	7.0	
Stomach		1		
	Leiomyoma	1	20.5	
Ileocecolic lymph node		1		
	Mucinous adenocarcinoma, orig. unknown	1	27.7	
Urogenital		61		
Uterus		39		
	Leiomyoma	30	25.1	15.0–34.8
	Myoma	3	24.1	23.3–25.2
	Uterine epidermoid carcinoma	3	29.2	24.6–33.3
	Neurilemoma within leiomyoma	2	25.4	22.7–28.0
	Uterine papillary carcinoma	1	25.8	
Mammary gland		10		
	Mammary ductular/intraductal carcinoma	8	26.5	18.3–35.8
	Mammary adenocarcinoma	1	26.8	
	Ductular adenoma	1	23.3	
Kidney		7		
	Renal cell carcinoma	4	26.1	21.6–33.1
	Renal tubular adenoma	3	26.4	21.5–31.8
Ovary		5		
	Endometrioid tumor	2	30.8	27.3–34.2
	Mucinous cystadenoma	1	25.4	
	Granulosa cell tumor	1	23.9	
	Papillary adenocarcinoma	1	23.3	
Endocrine		47		
Adrenal gland		16		
	Adrenal adenoma	12	20.2	8.5–27.8
	Adrenal myxoma	1	29.7	
	Epithelioid leiomyoma	1	29.3	
	Carcinoma	1	16.4	
	Hemangioma	1	27.8	

(Continued)

TABLE 1. (CONTINUED)

Neoplasm location	Histologic diagnosis	n	Age (years)	
			Diagnosis ^a	Range
Pancreas		12		
	Islet cell adenoma	11	25.7	4.9–32.3
	Exocrine pancreatic adenocarcinoma	1	25.0	
Thyroid gland		9		
	Adenoma	7	23.4	15.8–34.3
	Papillary carcinoma	1	34.3	
	C-cell carcinoma	1	29.2	
Pituitary gland		6		
	Adenoma	5	26.6	21.8–35.4
	Chromophobe adenoma	1	21.8	
Pancreatic duct		2		
	Pancreatic duct adenoma	1	22.9	
	Pancreatic duct carcinoma	1	37.3	
Parathyroid gland		2		
	Adenoma	1	28.7	
	Parathyroid gland carcinoma	1	23.2	
Respiratory		7		
Lung		7		
	Alveolar adenoma	5	25.6	19.9–35.4
	Papillary adenoma	1	24.8	
	Carcinoma, metastatic	1	20.2	
Skin		7		
Cervical	Basosquamous carcinoma	1	25.0	
Toe	Squamous cell carcinoma	1	31.2	
Knee	Papillary carcinoma	1	29.9	
Back	Spindle cell sarcoma	1	1.5	
Ischial callosity	Sarcoma	1	10.5	
Eyelid	Squamous papilloma	1	23.5	
Arm	Epidermoid carcinoma	1	28.0	
Hematopoietic		5		
	Lymphoma (multiple organs affected)	5	29.1	14.4–33.0
Musculoskeletal		3		
Arm	Rhabdomyosarcoma	1	38.0	
Thorax, ribs, and vertebrae	Chondrosarcoma	1	23.0	
Femur	Osteosarcoma	1	16.3	
Nervous system		3		
Cerebrum		2		
	Malignant neoplasm ^b	1	8.2	
	Protoplasmic astrocytoma	1	27.3	
Oculomotor and trigeminal nerve	Neurofibroma	1	23.8	
Total		260		

The average age of incidence for intestinal adenocarcinoma at all levels of the gastrointestinal system is 22.2 years.

^aIf more than one monkey, average for group is specified.

^bNot otherwise specified.

neoplasia diagnosed in two colonies of captive rhesus macaques for periods of 28 and 21 years respectively.

Materials and Methods

Colony 1

The Wisconsin National Primate Research Center (WNPRC) is an Association for Assessment and Accreditation of Laboratory Animal Care International accredited institution that has housed a yearly average of 1050 rhesus macaques

for the past 28 years. Monkeys are housed indoors on a 12 h light/dark cycle with controlled temperature and humidity. Juvenile monkeys live in small groups (5–10 animals with a dominant adult) and adult monkeys live in pairs or singly. They are fed a commercial nonhuman primate diet with supplemental fruit and allowed water *ad libitum*. All monkeys are closely observed and have a regular schedule of environmental enrichment. A complete necropsy with histologic analysis is performed on all monkeys, infant to adult, that die or are terminated.

Colony 2

Monkeys from the intramural NIA colony are housed at the Association for Assessment and Accreditation of Laboratory Animal Care International accredited National Institutes of Health (NIH) Animal Center. This colony consists of 120 monkeys that have been on long-term studies and are extensively monitored for 21 years. All monkeys are housed indoors on a 12 h light/dark cycle with controlled temperature and humidity. They consume a highly nutritious, natural ingredient, commercially prepared nonhuman primate chow that meets or exceeds requirements for vitamins and minerals. The monkeys are meal fed in two daily allotments, thus preventing obesity. Water is provided *ad libitum*. A complete necropsy with histologic analysis is performed on all monkeys that die or are terminated.

Data were gathered at WNPRC via a search of all necropsy and biopsy records in the electronic database using Systemized Nomenclature of Medicine coded keywords and terms. Necropsy and biopsy cases at NIA were identified from an electronic database and cross-referenced with a hardcopy tabulation of all identified disease conditions. Records from monkeys that had exposure to infectious or chemical agents known to predispose animals to the development of neoplasia were excluded as well as animals with serological evidence of Epstein-Barr virus, an oncogenic virus that is associated with B cell lymphoma (12, 15). Animals experimentally infected with simian immunodeficiency virus and genetically engineered simian human immunodeficiency viruses were also excluded. Within each organ system, tumors with the same histologic diagnosis were grouped, and the average age of incidence for specific tumor types was recorded.

Surgical and medical records from monkeys included in the survey were reviewed when biopsy and necropsy records provided insufficient information. Monkeys at both institutions that exhibited signs of clinical illness such as depression, anorexia, weight loss, or chronic diarrhea received comprehensive diagnostics including, but not limited to, physical examination, complete blood counts, serum chemistry analysis, radiographs, ultrasound, ultrasound guided biopsy, exploratory laparotomy, and surgical biopsy.

Results

Neoplasms were identified and tabulated based on organ system, histologic diagnosis, and age at diagnosis, which, in many cases, coincided with necropsy. Records reviewed at the WNPRC colony were limited to those dating back to 1980 and included 2540 monkeys. Records reviewed at NIA were limited to cohorts that had been closely followed since as early as 1987 and had an extensive recorded history. This included 120 monkeys. Results from both sites are tabulated together.

Of the 217 monkeys identified with neoplastic disease, there were 260 documented neoplastic events (Table 1). Single neoplasms were identified in 181 monkeys at biopsy and/or subsequent necropsy; 30 monkeys had two types; 5 monkeys had three different tumor types; and 1 monkey had four. The age of incidence (initial diagnosis) was tabulated based on age groupings that have been previously established in the literature (17, 19) (Table 2). The lowest incidence, 1.4%, occurred in animals less than 5 years of age, and 78.3% of all neoplasms were diagnosed in animals greater than 20 years of age. Necropsy records from 2000 to 2006 were further character-

TABLE 2. INCIDENCE OF NEOPLASIA IN RHESUS MACAQUES BY AGE GROUP

Age group (years)	Monkeys (n = 217)	Incidence (%)
<5	3	1.4
6–12	8	3.7
13–19	36	16.6
20–25	89	41.0
26–29	53	24.4
>30	28	12.9

ized to estimate the relative frequency of cancer cases among all deaths (Fig. 1). In monkeys greater than 26 years, cancer contributed to 50% of all deaths. For all groups that contained more than one monkey, the average age of incidence for spontaneous neoplasms was greater than 20 years, with one exception. Squamous cell carcinomas of the oral cavity were diagnosed at an average age of 17.6 years (Table 1).

The gastrointestinal system was most commonly affected, accounting for nearly half (48.8%) of all neoplasms identified, and adenocarcinomas of the large intestine (cecum and colon) were the majority (37%) of those. The urogenital and endocrine systems, 23.5% and 18.1%, respectively, were the site of nearly the remainder of the cases; whereas respiratory, skin, multicentric lymphoma/leukemia, musculoskeletal, and the nervous system combined made up less than 9% of the cases.

Within the gastrointestinal subgroup, adenocarcinomas were the most prevalent type of tumors identified. They most commonly affected the colon (41.7%) and the ileocecolic junction (30%). These neoplasms often formed an annular or "napkin-ring" constriction with dilation of the intestines proximal to the tumor (Fig. 2). Microscopically adenocarcinomas penetrated the muscularis mucosae and invaded the inner and outer muscular layers of the intestinal wall (Fig. 3). Invasion of lymphatic vessels, adjacent lymph nodes (LNs), and extension through the intestinal serosa into the mesentery occurred in advanced cases.

Fourteen cases were initially diagnosed by surgical biopsy; and in five of these monkeys, there were metastases to local LNs and/or distant sites (Table 3). In one additional case, a biopsy identified a mucinous adenocarcinoma within the ileocecolic LN, but the primary intestinal tumor was not identified at necropsy.

Surgical excision of intestinal tumors frequently occurs due to the high incidence of intestinal adenocarcinomas and protocol requirements for the maintenance of aging cohorts of monkeys. Survival after excision of an intestinal carcinoma from 14 cases noted at WNPRC ranged from 1 to 66 months (Table 3). An additional three monkeys are currently alive at 16, 28, and 29 months postsurgery. Of the six animals that died within 6 months of surgery, none had evidence of dehiscence of the anastomosis site. However, gastrointestinal problems persisted such as diarrhea, anorexia, and hyperphagia with weight loss.

The presence of LN metastasis at the time of biopsy was not predictive for tumor recurrence or the length of survival. Only 40% of the animals with LN invasion at biopsy had tumor recurrence at necropsy. Tumor recurrence occurred in approximately half of the animals regardless of survival period. Further characterization of these cases is underway to better understand the factors associated with survival.

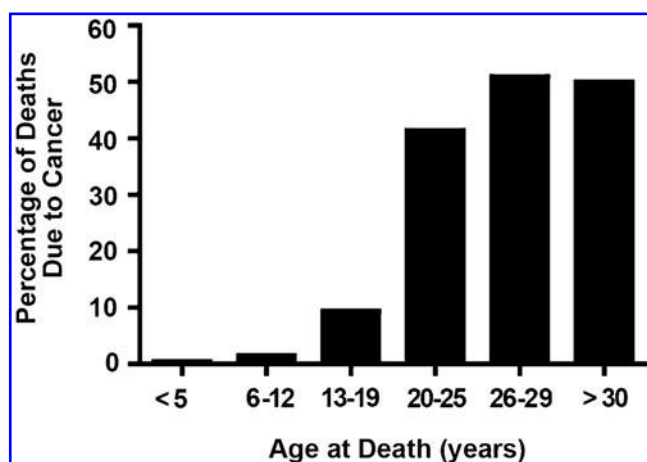


FIG. 1. Percentage of the total deaths from the years 2000–2006 that were due to cancer.

Most tumors of the parotid salivary gland in humans are benign. Of the three cases identified in the monkey records, one was an adenocarcinoma, with local invasion of skin and connective tissue surrounding the ear. All six oral neoplasms were squamous cell carcinomas involving the mucous membranes and/or mucocutaneous junctions of the lips. Only one case metastasized to the mandibular LNs. There were six cases of carcinoma of the duodenal ampulla of Vater where the common bile duct and pancreatic duct join. The most consistent findings were anemia (100%), decreased serum albumin (100%), and weight loss (83%). Only one animal had icterus (18).

Urogenital neoplasms were the second most common subgroup, and 30 out of 39 of these were uterine leiomyomas, a benign smooth muscle tumor. Two leiomyomas had concurrent well-circumscribed neurilemmomas within the leiomyoma. Also known as fibroids, these tumors are diagnosed in over half of women over the age of 40 (12). The three epidermoid carcinomas, a carcinoma of the uterine endometrium, had extensive metastases to adjacent organs including the cervix, ovary, urinary bladder, peritoneum, and lung. Two of the three epidermoid carcinomas also metastasized to the

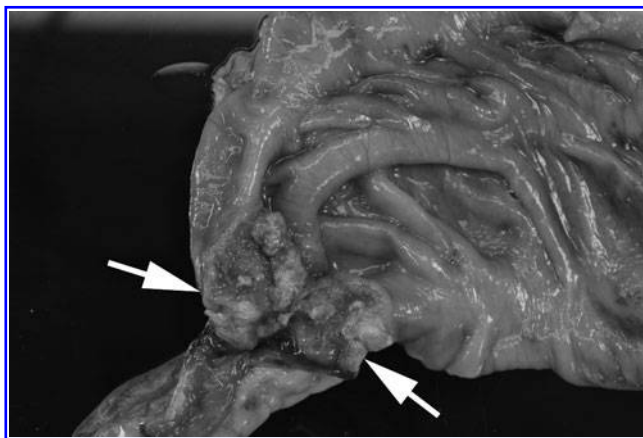


FIG. 2. "Napkin-ring" constriction of the cecocolic junction caused by an annular adenocarcinoma (arrows) in a 23-year-old female.

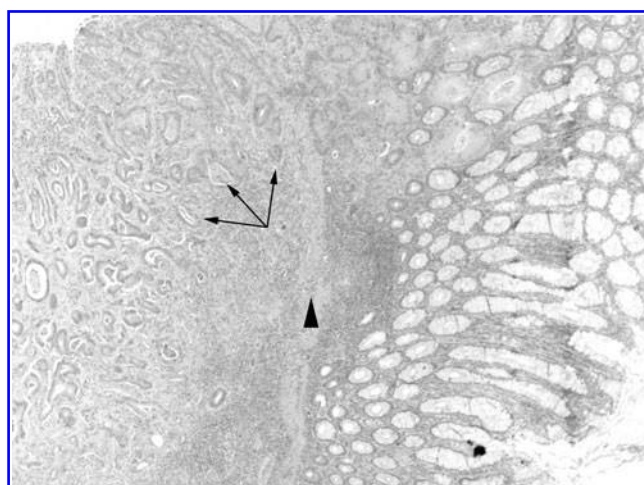


FIG. 3. Photomicrograph of an adenocarcinoma of the colon showing neoplastic glands (arrows) surrounded by scirrhous stroma penetrating the muscularis mucosae (arrow head) and infiltrating into the muscle wall.

liver. The single reported papillary carcinoma of the uterus extended to the cervix.

Ovarian neoplasms included a granulosa cell tumor, a sex cord stromal tumor that may produce estrogen; a mucinous cystadenoma; two endometrioid tumors of epithelial cell origin; and a papillary adenocarcinoma. The papillary adenocarcinoma metastasized to the omentum and retroperitoneum. One of the endometrioid tumors progressed to carcinomatosis of the peritoneum and involved the colon, LNs, small intestine, omentum, and diaphragm.

Eight out of 10 mammary neoplasms were intraductal carcinomas. One metastasized to the lung, and a second involved both the right and left mammary glands and metastasized to the axillary LNs and adjacent subcutaneous tissue. Two mammary carcinomas were surgically excised but locally recurred. The animals survived 5 and 21 months, respectively, and were euthanized due to unrelated illnesses.

Renal neoplasms were almost evenly divided between renal tubular adenomas and renal cell carcinomas, three and four out of seven, respectively. There was no difference in age at diagnosis between these two conditions. One renal cell carcinoma metastasized to the peritoneum and pelvic cavity, whereas all others remained within the renal capsule.

Endocrine neoplasms were relatively common, making up 18.1% of the cases recorded. None of the thyroid tumors,

TABLE 3. SURVIVAL TIME AFTER SURGICAL EXCISION OF INTESTINAL NEOPLASIA (N = 14)

Survival time (months)	Number of monkeys	Lymph node invasion at biopsy	Tumor recurrence at necropsy
<6	6	3	3
6	1	0	0
12	2	1	2
18	1	1	0
24	1	0	1
30	1	0	0
>48	2	0	1

parathyroid tumors, adrenal adenomas, pituitary adenomas, or intraductular carcinomas of the pancreas metastasized. Pancreatic islet cell adenomas did not metastasize, but two animals diagnosed at biopsy had additional islet cell adenomas at necropsy at 3 and 55 months after the original diagnosis. The islet cell adenomas were not the cause of either animal's demise. Adrenal adenomas were often noted to be multicentric within one or both glands. A single adrenal gland carcinoma widely metastasized to the stomach, gall bladder, liver, kidney, urinary bladder, colon, pancreas, diaphragm, lung, heart, and intercostal muscles.

Dermal neoplasms varied from a squamous cell carcinoma of the toe, a papillary carcinoma of the knee, a spindle cell sarcoma of the subcutaneous tissue of the back, a sarcoma of the ischial callosity, and an aggressive epidermoid carcinoma of the arm that widely metastasized. A basosquamous cell carcinoma was removed from the neck of a 25-year-old male. No recurrence was noted on radiographs taken 3 months after surgery. The monkey is currently alive.

There were three cases of multicentric lymphoma, one case of small intestinal lymphoma, and one case of lymphocytic leukemia in this population of 217 monkeys. The lymphocytic leukemia was diagnosed in a 33-year-old male that presented with a persistently elevated white blood cell count and enlarged inguinal LNs. He has not received cancer specific treatment and is currently alive 3 years postdiagnosis.

Three animals were identified with musculoskeletal system neoplasms. One animal had a combined-type osteosarcoma of the left femur (2). There were no metastases noted on radiographs and the limb was amputated. The animal was closely monitored, and pulmonary metastases were noted 23 months after removal of the primary tumor. There was no increase in respiratory effort, but progressive weight loss necessitated euthanasia 39 months after the initial diagnosis. Tumor metastasis to the left lung was histologically confirmed. A rhabdomyosarcoma was diagnosed in the arm of a 38-year-old male. Fine needle aspirates before necropsy were nondiagnostic. A rapidly growing chondrosarcoma tumor was identified in a 23-year-old female. The mass originated under the scapula and involved the ribs and thoracic vertebrae. Needle and punch biopsies were nondiagnostic in this case.

Only three cases of neoplasia were noted within the central nervous system: a protoplasmic astrocytoma of the cerebrum, a neurofibroma of the oculomotor and trigeminal nerves, and a malignant neoplasm of the cerebrum that could not be further characterized despite additional diagnostics.

Discussion

The findings of the current survey correlate well with previous reports from rhesus macaque colonies in which the incidence of geriatric disorders, including cancer, significantly increased over the age of 20 years (13, 16, 17). In the current survey, the incidence of all types of neoplasms increased with age, with 77% of the tumors occurring in animals greater than 20 years old. Of the older age groups, the 20- to 25-year group had the highest number of tumors but it also had the greatest number of monkeys in it. When neoplasms were tabulated as a percentage of the number of monkeys in each of the older groups, it confirmed an age-associated increase in incidence in the age groups greater

than 20 years. This is comparable to the age-related incidence of colonic adenocarcinoma in progressively older groups of rhesus macaques, as previously reported (17).

The most prevalent neoplasm identified was adenocarcinoma of the intestines. The average age of incidence was 22.2 years, and the colon was the most commonly affected site. Previous studies have characterized the clinical, gross, and histologic characteristics of this neoplasm (13, 17, 19). A study of the rhesus macaque colony at the University of Illinois reported diagnoses of 25% mucinous adenocarcinomas and 75% adenocarcinomas (13). The results of the current survey of the WNPRC and NIA colonies are similar with the mucinous form comprising 25% of the intestinal adenocarcinomas diagnosed. Mucinous adenocarcinomas account for only 10% of colorectal cancers in humans and are associated with hereditary nonpolyposis syndrome, ulcerative colitis, and therapeutic radiation (7). A review of biopsy and necropsy specimens, pedigree information, and genetic material in animals diagnosed with intestinal adenocarcinomas to further characterize this neoplasm is warranted.

Both aging rhesus macaque colonies were closely monitored for gastrointestinal dysfunction to identify cancerous growths for early intervention. Surgical excision of a suspected adenocarcinoma was standard practice. Cases with both excisional biopsy and necropsy data were reviewed for tumor recurrence and survival. Seventy-seven percent of the biopsy cases had no evidence of local metastasis at the time of surgery. Of the cases with no metastasis, 56% had tumor recurrence at necropsy. Survival rates were variable and did not correlate with the incidence of metastases at the time of biopsy or tumor recurrence. Careful staging of biopsy material and review of surgical practices may be necessary to truly evaluate the effect of surgical excision on survival.

Carcinoembryonic antigen (CEA) monitoring for colorectal cancer in humans has been prescribed but remains controversial. It is a protein that has been associated with certain tumors and has been used as a tumor marker, in particular for the gastrointestinal tract. An increasing serum CEA value is associated with the progression or recurrence of the cancer in humans; however, there are still substantial limitations for the test (8). Preliminary information on this test in rhesus monkeys does not support its use for diagnostic purposes. Serum and plasma from a small number of monkeys was tested for the presence of CEA at the California National Primate Research Center. In 9 out of 10 of the cases, values fell below 0.5 ng/ml, and the serologic testing failed to detect changes after surgical resection or tumor dissemination (19). Similarly, the NIA assessed a number of serum and plasma samples from monkeys with known gastrointestinal tumors and CEA was not elevated.

There was a small cohort of monkeys diagnosed with carcinoma of the ampulla of Vater. In humans, this is an uncommon tumor arising from the epithelium of the common bile duct or the major pancreatic duct and accounts for only 0.2% of all intestinal tumors (5). Patients commonly present with jaundice and weight loss (11). LN metastases is an important predictor for survival and is noted in 50% of human cases at the time of diagnosis (1, 5), but the liver is the most common site of distant metastases (1). Rhesus macaques had metastasis to the LNs, liver, lung, and other sites in 50% of cases. Histologically, all the tumors were similar, and 67% of the cases had concurrent cholangiohepatitis (18).

Spontaneous neoplasia in rhesus macaques mimics, in several ways, the development of cancer in people. Although there are significant species differences in the occurrence and the biological behavior of certain tumors in the rhesus macaque when compared with humans, their close genetic relationship and minimal exposure to many of the known and suspected carcinogens allow them to serve as a value model for comparative oncology. Characterizing the spontaneous cancers of rhesus macaques also provides valuable information for the veterinarians and staff responsible for the care and longevity of this valuable research resource.

Acknowledgments

This work was supported by the NIH grant RR000167 and in part by the Intramural Research Program of the NIH, NIA. We thank the animal care and veterinary staff at both sites for their care of the primates. Additionally, thanks to the individuals who have worked in the WNPRC Pathology unit over the past 28 years. Additional thanks to Jennifer Young for editorial assistance and Dan Longo for his suggestions. NIA is grateful for the contributions of their primary pathologist Dr. Mark Bryant.

Author Disclosure Statement

No competing financial interests exist.

References

1. Barton RM and Copeland EM. Carcinoma of the ampulla of Vater. *Surg Gynecol Obstet* 156: 297–301, 1983.
2. Beam SL. Combined-type osteosarcoma in a rhesus macaque. *Vet Pathol* 42: 374–377, 2005.
3. Beniashvili DS. An overview of the world literature on spontaneous tumors in nonhuman primates. *J Med Primatol* 18: 423–437, 1989.
4. Bodkin NL, Alexander TM, Ortmeier HK, Johnson E, and Hansen BC. Mortality and morbidity in laboratory-maintained rhesus monkeys and effects of long-term dietary restriction. *J Gerontol Biol Sci* 58: 212–219, 2003.
5. Carter JT, Grenert JP, Rubenstein L, Stewart L, and Way LW. Tumors of the ampulla of Vater: Histopathologic classification and predictors of survival. *J Am Coll Surg* 207: 210–218, 2008.
6. Colman RJ and Kemnitz JW. *Methods in Aging Research*. Boca Raton: CRC Press, 249–267, 1998.
7. Cooper HS. Intestinal neoplasms. In: *Sternberg's Diagnostic Surgical Pathology*, edited by Mills SE, Carter D, Greenson JK, Oberman HA, Reuter V, Stoler MK. Philadelphia, PA: Lippencott Williams & Wilkins, 2004, pp. 1545–1601.
8. Fakih MG and Padmanabhan A. CEA monitoring in colorectal cancer. What you should know. *Oncology (Williston Park)* 20: 579–587, 2006.
9. Jemal A, Siegel R, Ward E, Hao Y, Xu J, Murray T, and Thun MJ. Cancer statistics, 2008. *CA Cancer J Clin* 58: 71–96, 2008.
10. Kemnitz JW, Holston KA, and Colman RJ. Nutrition, aging and reproduction in rhesus monkeys. In: *Nutrition and Reproduction*. Hansel W, Bray GA, Ryan DH, eds. Baton Rouge, LA: Louisiana State University Press, 180–195, 1998.
11. Kim RD, Kundhal PS, McGilvray ID, Catral MS, Taylor B, Langer B, Grant DR, Zogopoulos G, Shah SA, Greig PD, and Gallinger S. Predictors of failure after pancreaticoduodenectomy for ampullary carcinoma. *J Am Coll Surg* 202: 112–119, 2006.
12. Kumar V, Abbas AK, and Fausto N. (eds). *Robbins and Cotran Pathologic Basis of Disease*. Philadelphia, PA: Elsevier Saunders, 256–257, 284, 2005.
13. Rodriguez NA, Garcia KD, Fortman JD, Hewett TA, Bunte RM, and Benett BT. Clinical and histopathological evaluation of 13 cases of adenocarcinoma in aged rhesus macaques (*Macaca mulatta*). *J Med Primatol* 31: 74–83, 2002.
14. Roth GS, Mattison JA, Ottinger MA, Chachich ME, Lane MA, and Ingram DK. Aging in rhesus monkeys: relevance to human health interventions. *Science* 304: 1423–1426, 2004.
15. Suzuki J, Goto S, Kato A, Hashimoto C, Miwa N, Takao S, Ishida T, and Fukuoka A. Malignant lymphoma associated with simian Epstein-Barr virus infection in a Japanese macaque (*Macaca fuscata*). Proceedings of AZWMP 2006. Chulalongkorn University Faculty of Veterinary Sciences, Bangkok, Thailand, October 26–29, 2006.
16. Uno H. Age-related pathology and biosenescent markers in captive rhesus macaques. *Age* 20: 1–13, 1997.
17. Uno H, Alsum P, Zimbric ML, Houser WD, and Thomson JA. Colon cancer in aged captive rhesus monkeys (*Macaca mulatta*). *Am J Primatol* 44: 19–27, 1998.
18. Osborne AL and Bolton ID. Ampullary carcinoma in a group of aged rhesus macaques (*Macaca mulatta*). *Comp Med* 54: 438–442, 2004.
19. Valverde CR, Tarara RP, Griffey SM, and Roberts JA. Spontaneous intestinal adenocarcinoma in geriatric macaques (*Macaca sp.*). *Comp Med* 50: 540–543, 2000.

Address correspondence to:

Dr. Heather A. Simmons
Wisconsin National Primate Research Center
University of Wisconsin
1220 Capitol Court
Madison, WI 53715-1299

E-mail: hsimmons@primate.wisc.edu

Date of first submission to ARS Central, May 18, 2010; date of acceptance, June 2, 2010.

Abbreviations Used

CEA = carcinoembryonic antigen
LN = lymph node
NIA = National Institute on Aging
NIH = National Institutes of Health
WNPRC = Wisconsin National Primate Research Center

This article has been cited by:

1. Caleb E. Finch, Steven N. Austad. 2012. Primate aging in the mammalian scheme: the puzzle of extreme variation in brain aging. *AGE* . [[CrossRef](#)]
2. Andrew D. Miller Neoplasia and Proliferative Disorders of Nonhuman Primates 325-356. [[CrossRef](#)]
3. Rozalyn M. Anderson , Ricki J. Colman . 2011. Prospects and Perspectives in Primate Aging Research. *Antioxidants & Redox Signaling* **14**:2, 203-205. [[Abstract](#)] [[Full Text HTML](#)] [[Full Text PDF](#)] [[Full Text PDF with Links](#)]